

Case Report

Acute respiratory distress syndrome in a case of *Plasmodium vivax* malaria

Atiullah Malik*, Yadav Ponvijaya, Kshithija Sajjan, Chirag Gurbani

Department of Medicine, Dr. D. Y. Patil Medical College, Dr. D. Y. Patil Vidyapeeth, Pune, Maharashtra, India

Received: 21 December 2020

Revised: 06 February 2021

Accepted: 08 February 2021

*Correspondence:

Dr. Atiullah Malik,

E-mail: malik9002atiullah@gmail.com

Copyright: © the author(s), publisher and licensee Medip Academy. This is an open-access article distributed under the terms of the Creative Commons Attribution Non-Commercial License, which permits unrestricted non-commercial use, distribution, and reproduction in any medium, provided the original work is properly cited.

ABSTRACT

Acute respiratory distress syndrome (ARDS) is a life threatening complication of many infectious diseases like malaria, H1N1, bacterial pneumonia, and leptospira. Malaria is an important treatable cause of ARDS. ARDS can develop either at initial presentation or after initiation of treatment when the parasitaemia is falling and patient is improving. 58 year old female presented with high grade fever and breathlessness since 5 days. Arterial blood gas (ABG) on admission showed type 1 respiratory failure and chest X-ray was suggestive of ARDS. Thus patient was shifted to intensive care unit and was put on non-invasive ventilation. PBS was positive for *Plasmodium vivax* malaria and patient was started on antimalarial drugs. Considering the epidemic of H1N1 swab was sent for polymerase chain reaction (PCR) which turned out to be negative. Thus antimalarial and supportive treatment for ARDS was continued. Patient was discharged on day 11 and started on tablet primaquine to prevent relapse. ARDS is a hard to predict late complication of severe malaria. ARDS in malaria is a disease with high mortality. Early diagnosis and institution of specific antimalarial treatment along with assisted ventilation can be life-saving.

Keywords: Acute respiratory distress syndrome, Non-invasive ventilation, *Plasmodium vivax*

INTRODUCTION

Malaria is an increasingly common public health problem and the increase in number of cases in endemic areas, human migration, and increased world travel have led to many cases of imported malaria in countries where it has been eradicated, making it a global health problem.^{1,4} The manifestations of severe malaria caused by *Plasmodium falciparum* include cerebral malaria, severe anemia, hemoglobinuria, pulmonary edema or acute respiratory distress syndrome (ARDS), disseminated intravascular coagulation, cardiovascular collapse and shock, acute kidney failure, hyperparasitemia, metabolic acidosis and hypoglycemia.⁵ *Plasmodium vivax* is endemic in countries of Asia and South America, and usually presents as benign febrile acute disease.⁶ Severe pulmonary involvement (ARDS) in malaria is rarely associated with *vivax* malaria

and recovery is usual. Here we report a rare case of ARDS caused by *Plasmodium vivax*.

CASE REPORT

A 58 year old female came to medicine OPD with complaints of high grade fever with chills and severe breathlessness since 5 days, which was associated with sore throat and generalised bodyache. No significant past history was present. On examination, temperature was 102 °F, pulse rate (PR) - 110 bpm, blood pressure (BP) - 130/80 mmHg, respiratory rate (RR) - 20/min, peripheral saturation was 88% on room air. Respiratory system examination revealed bilateral basal crepitations. Other systems were within normal limits. Routine lab investigations were within normal limits.

ABG on admission showed pH 7.36, PCO₂ 29.8 mmHg, PaO₂ 69 mmHg, HCO₃⁻ 17 mmol/l and PaO₂/ FiO₂ ratio was 190. Peripheral blood smear showed *Plasmodium vivax*. Other fever profile tests were negative. Considering the epidemic of H1N1 throat swab for PCR was done which turned to be negative. Tracheal aspirates and blood cultures showed no growth. Chest X-ray was suggestive of bilateral alveolar opacities in lower zone with consolidation. Patient was diagnosed with ARDS secondary to *vivax* malaria. Due to the severe respiratory complications, patients was shifted to ICU and was started on non-invasive ventilation. She was treated with injection artesunate, injection amoxicillin clavunate, injection hydrocortisone, tablet doxycycline and tablet oseltamivir. Oral anti-malarials were continued. Patient was discharged on day 11 on tablet primaquine and is on regular follow up.

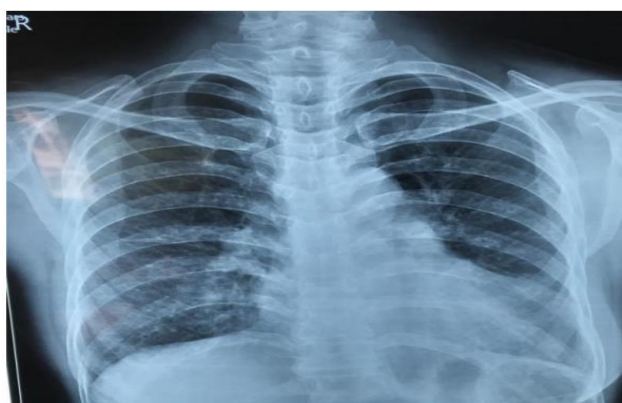


Figure 1: Chest X-ray PA view shows alveolar opacities in lower zone bilaterally.

DISCUSSION

Severe *vivax* malaria typically presents with low parasitemia, fever with chills, cough and respiratory distress (ARDS), abdominal pain, diarrhea, severe anaemia, pancytopenia, jaundice, hepatitis, myocarditis, acute renal failure, glomerulonephritis, coma or convulsion. Clinically, patients usually present with acute breathlessness which rapidly progress to respiratory failure either at disease presentation or after treatment when clinical improvement is taking place and the parasitemia is falling. Pregnant women are particularly prone to developing pulmonary edema.⁷ In pregnant women, *Plasmodium vivax* infection can result in low birth weight.^{8,9} Lung involvement in malaria has been recognized since ages, yet our knowledge about its pathogenesis and management is limited. Pulmonary edema is the most severe form of lung involvement. Increased alveolar capillary permeability causing intravascular fluid loss into the lungs is the main pathophysiologic mechanism.⁷ Several pulmonary syndromes in severe *vivax* malaria have been described, such as acute non-cardiogenic pulmonary edema, ARDS, and interstitial pneumonia.¹⁰⁻¹⁵ ARDS often complicates critical illness. Diagnosis of ARDS is based on fulfilling 3 criteria: acute onset (within 1 week), bilateral opacities on

chest X-ray and PaO₂/FiO₂ (arterial to inspired oxygen) ratio of ≤ 300 on positive end- expiratory pressure (PEEP) or continuous positive airway pressure (CPAP) ≥ 5 cm H₂O.¹⁴

The Berlin definition proposed 3 categories of ARDS based on the severity of hypoxemia: mild- Pao₂/Fio₂ >200 and ≤ 300 and mm Hg, moderate- Pao₂/Fio₂ >100 mm Hg and ≤ 200 mm Hg and severe- Pao₂/Fio₂ ≤ 100 mm Hg along with explicit criteria related to timing of the syndrome's onset, origin of edema, and the chest radiograph findings.¹⁴

A recent study demonstrated that clinically uncomplicated cases of both *falciparum* and *vivax* malaria presented with compromised pulmonary function due to small airway obstruction, gas exchange alterations, and increased pulmonary phagocytic activity.¹⁶ Researchers suggest that an accumulation of pulmonary monocytes occurs leading to an intravascular inflammatory response, which contributes to pulmonary manifestations in malaria.¹⁷ Severe pulmonary complications of *vivax* malaria usually appear from six hours to eight days after the initiation of anti-malarial treatment. In some cases, worsening of the clinical picture was seen after reduction of parasite counts, reinforcing the possibility of an immune mediated inflammatory response.^{14,15,17}

In most reported cases of ARDS due to *vivax* malaria, diagnosis was made by PBF examination without molecular diagnostic confirmation, thus co-infection with *P. falciparum* could not be ruled out, and most of the reported cases were treated for both *P. falciparum* and *P. vivax*.¹⁸

Anstey et al raised the hypothesis that the widespread use of chloroquine and doxycycline in malaria-endemic areas could be attenuating or diminishing the number of severe cases of *vivax* malaria because of the anti-inflammatory properties of these drugs.¹⁶

The possible role of an inflammatory mechanism in pulmonary damage by *vivax* malaria suggests a potential benefit with the use of corticosteroid therapy.¹⁷ However, there is no evidence that supports this therapeutic approach.

Treatment of ARDS usually requires institution of invasive mechanical ventilation with high PEEP. Agarwal et al, found that use of NIV in *vivax* malaria related ARDS is associated with a good outcome.¹⁹

The use of antimalarial treatment with respiratory support is associated with a good prognosis in most cases of severe pulmonary involvement due to *vivax* malaria.¹⁴

CONCLUSION

Our patient presented with signs of severe malaria and ARDS and responded to non-invasive ventilation.

Recommendations

P. vivax malaria should be considered in the differential diagnosis of patients with acute febrile syndrome and respiratory symptoms before anti-malarial treatment. The use of lung-protective ventilation may help to reduce mortality from malaria-induced ARDS.

Funding: No funding sources

Conflict of interest: None declared

Ethical approval: Not required

REFERENCES

1. Mohan A, Sharma SK, Bollineni S. Acute lung injury and acute respiratory distress syndrome in malaria. *J Vector Borne Dis.* 2008;45(3):179-93.
2. Graça L, Abreu IG, Santos AS, Graça L, Dias PF, Santos ML. Descriptive Acute Respiratory Distress Syndrome (ARDS) in adults with imported severe *Plasmodium falciparum* malaria: A 10 year-study in a Portuguese tertiary care hospital. *PLoS One.* 2020;15(7):e0235437.
3. Greenwood B, Mutabingwa T. Malaria in 2002. *Nature.* 2002;415:670-2.
4. Maitland K., Bejon P., Newton C.R. Malaria. *Curr Opin Infect Dis* 2003;16:389-95.
5. White NJ, Ashley EA. Malaria, Harrison's principles of internal medicine. 20th edition.
6. Lomar AV, Vidal JE, Lomar FP, Barbas CV, de Matos GJ, Boulos M. Acute respiratory distress syndrome due to vivax malaria: case report and literature review. *Braz J Infect Dis.* 2005;9(5):425-30.
7. Taylor WR, Cañon V, White NJ. Pulmonary manifestations of malaria: recognition and management. *Treat Respir Med.* 2006;5(6):419-28.
8. Baron RM, Levy BD. Acute respiratory distress syndrome. Harrison's principles of internal medicine 20th edition. Chapter 294. 2012;2030,
9. Reid PT, Innes JA. Respiratory diseases: acute respiratory distress syndrome. *Davidson's Principles & Practice of Medicine*, 22nd edition. 2017;686.
10. Torres JR, Perez H, Postigo MM, Silva JR. Acute non-cardiogenic lung injury in benign tertian malaria. *Lancet.* 1997;350:31-2.
11. Pukrittayakamee S, Chantira A, Vanijanonta S, White NJ. Pulmonary edema in vivax malaria. *Trans R Soc Trop Med Hyg.* 1998;92:421-2.
12. Islam N, Qamruddink K. Unusual complications in benign tertian malaria. *Trop Geogr Med.* 1995;47:141-3.
13. Carlini ME, White AC, Atmar RL. Vivax malaria complicated by adult respiratory distress syndrome. *Clin Infect Dis.* 1999;28:1182-3.
14. Tanios MA, Kogelman L, McGovern B, Hassoun P. Acute respiratory distress syndrome complicating *Plasmodium vivax* malaria. *Crit Care Med.* 2001;29:665-7.
15. Munteis E, Melliborsky L, Marques MA. Pulmonary involvement in a case of *Plasmodium vivax* malaria [letter]. *Chest.* 1997;111:834-5.
16. Anstey NM, Jacups SP, Cain T, Pearson T, Ziesing PJ, Fisher DA, et al. Pulmonary manifestations of uncomplicated falciparum and vivax malaria: Caught, small airways obstruction, impaired gas transfer, and increased pulmonary phagocytic activity. *J Infect Dis.* 2002;185:1326-34.
17. Mukherjee T, Lavania AK. Acute Respiratory Distress Syndrome due to Vivax Malaria. *Med J Armed Forces India.* 2008;64(4):365-6.
18. Sarkar S, Saha K, Das CS. Three cases of ARDS: An emerging complication of *Plasmodium vivax* malaria, *Lung India.* 2010;27(3):154-7.
19. Agarwal R, Nath A, Gupta D. Noninvasive ventilation in *Plasmodium vivax* related ALI/ARDS. *Intern Med.* 2007;46:2007-11.

Cite this article as: Malik A, Ponvijaya Y, Sajjan K, Gurbani C. Acute respiratory distress syndrome in a case of *Plasmodium vivax* malaria. *Int J Community Med Public Health* 2021;8:1515-7.