

## Original Research Article

# Frequency of turner syndrome: findings from a tertiary healthcare diagnostic laboratory of India

Shailesh Pande<sup>1\*</sup>, Vidya Salaskar<sup>1</sup>, Anurita Pais<sup>1</sup>, Gauri Pradhan<sup>1</sup>,  
Smita Patil<sup>1</sup>, Chaitali Parab<sup>1</sup>, Sunmeet Matkar<sup>2</sup>

<sup>1</sup>Department of Cytogenetics, <sup>2</sup>Medical Communications Research and Development, Metropolis Healthcare Laboratory, Kurla (W), Mumbai, Maharashtra, India

**Received:** 15 September 2017

**Revised:** 08 October 2017

**Accepted:** 09 October 2017

### \*Correspondence:

Dr. Shailesh Pande,

E-mail: [shailesh.pande@metropolisindia.com](mailto:shailesh.pande@metropolisindia.com)

**Copyright:** © the author(s), publisher and licensee Medip Academy. This is an open-access article distributed under the terms of the Creative Commons Attribution Non-Commercial License, which permits unrestricted non-commercial use, distribution, and reproduction in any medium, provided the original work is properly cited.

## ABSTRACT

**Background:** Turner syndrome (TS) is the most common chromosomal abnormality reported in the females. Objective of this retrospective study was to determine the frequency of turner Syndrome and its various cytogenetic types in samples suspected to be of turner syndrome, received in the Department of Cytogenetics, Metropolis Healthcare laboratory, Mumbai, Maharashtra, India.

**Methods:** The current study was performed on 935 clinically suspected samples with Turner Syndrome within the age group of 01-16 years. Peripheral blood (2-3 ml) in Sodium heparin Vacutainers was collected from all the patients, the cultures were set & analysed by GTG-banding at 450-550 band level Results were reported as per the guidelines of the International System for Human Cytogenomic Nomenclature (ISCN) and The College of American Pathologists (CAP) and National Accreditation Board for Testing and Calibration Laboratories (NABL).

**Results:** In our study, out of the total 935 samples referred to Metropolis Healthcare Ltd, about 348 had cytogenetically turner or Turner variant findings. Further, out of 348 cases, 69 cases were detected to have presence of single X chromosome (19.83%), mosaic pattern in 116 cases (33.33%), presence of Y chromosome in 63 cases (18.10%) polymorphic variation in 58 cases (16.67%), presence of only isochromosome Xq in 9 cases (2.59%) and 33 cases (9.48%) with other or additional abnormalities.

**Conclusions:** The cytogenetic confirmation and pattern of chromosomal aberration is very important as early detection may help to improve the quality of life especially in patients with cytogenetically Turner variant pattern with presence of Y chromosome.

**Keywords:** Karyotype, Monosomy, Mosaic, Metropolis healthcare Ltd, Turner's syndrome, India

## INTRODUCTION

Turner syndrome (TS) is the most common chromosomal abnormality reported in the females.<sup>1</sup> The contribution of this chromosomal abnormality is approximately 3% of all female fetuses. Most of the 45, X fetuses are not able to survive early and approximately only 1% of affected fetuses survive to full term and it is estimated that approximately 1 in 2500 live born phenotypic females are

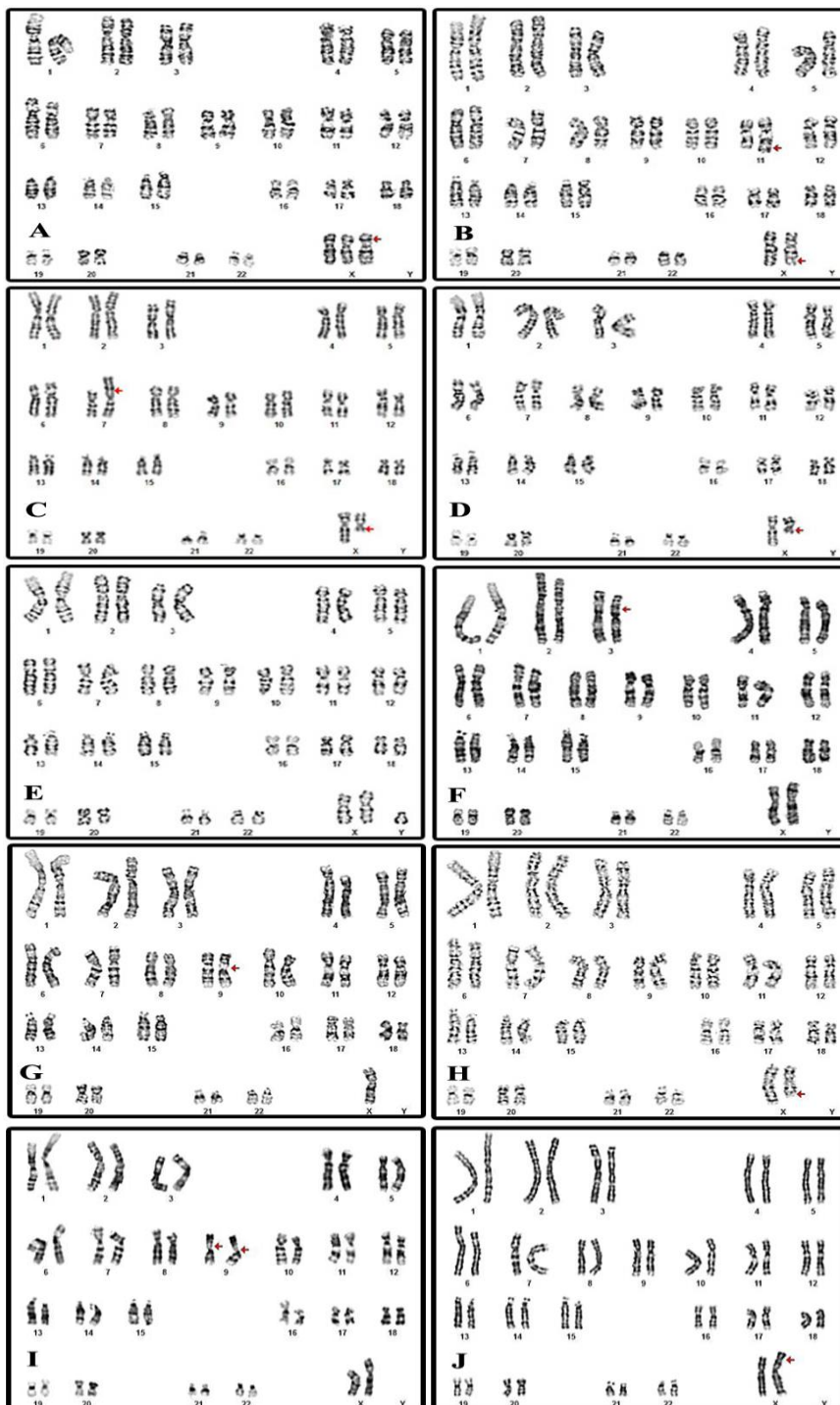
affected.<sup>2</sup> An association of small stature and defective ovarian development has been noted by some researchers who has classified this disorder as a sexagen dwarfisim.<sup>3</sup> In 1938, turner described in expanded way the syndrome of small stature, sex infantilism, webbed neck and cubitus valgus.<sup>4</sup> Objective of this retrospective study was to determine the frequency of turner syndrome and its various cytogenetic types in samples suspected to be of turner syndrome, received in the Department of

Cytogenetics, Metropolis Healthcare laboratory, Mumbai, Maharashtra, India.

**METHODS**

The current study was performed on 935 clinically suspected samples with Turner syndrome within the age

group of 01-16 years. All the study samples were referred to the Department of Cytogenetics, Metropolis Healthcare laboratory, Mumbai, Maharashtra, India during the period of 2 years from January-2015 through December-2016.



**Figure 1: Different patterns of karyotype findings observed in all the study samples suspected to be turner syndrome. (A: 47,XXX, B: 46,X,t(x;11)(q24,q23.3), C: 46,X,t(X;7)(q13;p15), D: 46,X,del(X)(q13), E: 47,XXY, F: 46,XX,inv(3)(p<sup>21.3</sup>,p<sup>24.2</sup>), G: 45,X,inv(9)(p11q13), H: 46,X,del(X)(q22), I: 46,X,inv(9)(p11q13)X2, J:46,X,der(X)t(X)(p<sup>22.1</sup>).**

For each individual case, around 20-30 metaphases were analysed and for the mosaic cases around 50-100 metaphases were analysed. Wherever necessary, Fluorescent in situ hybridization (FISH) test was performed to confirm the presence of low grade sex chromosomal mosaicism and for SRY gene depending upon clinical findings in the in-house cases and history provided for referred cases after discussing with the referring clinician.

## RESULTS

In our study, out of the total 935 samples referred to Metropolis Healthcare Ltd, about 348 had cytogenetically turner or Turner variant findings. Further, out of 348 cases, 69 cases were detected to have presence of single X chromosome (19.83%), mosaic pattern in 116 cases (33.33%), presence of Y chromosome in 63 cases (18.10%) polymorphic variation in 58 cases (16.67%), presence of only isochromosome Xq 9 cases (2.59%) and 33 cases (9.48%) with other or additional abnormalities.

## DISCUSSION

According to the several literature reports, Turner Syndrome is the most common chromosomal abnormality in females.<sup>5-8</sup> But, only 1% of conceptus with this abnormality survives up to full term.<sup>9</sup> The babies born with this type of chromosomal abnormality have wide range of clinical presentation depending upon the chromosomal abnormality found in karyotyping. A typical turner patient may have small stature, ovarian dysgenesis/dysfunction, congenital lymphedema broad chest with widely spaced nipples, short neck, webbed posterior neck, cardiac defect like bicuspid aortic valve or coarctation of aorta, renal anomalies in the form of horseshoe kidney, perceptible hearing impairment. The congenital lymphedema usually recedes in early infancy. The small size is often seen at birth and from birth to 3 years the growth rate is normal but bone maturation delay is usually observed after 12 years the growth rate decreases. It is also observed that XO abortus have nearly normal ovaries in early fetal life, the ovary degenerates rapidly in the later stages.

**Table 1: Different types of chromosomal abnormalities reported in our study.**

Karyotype	Frequency
45,X	69
46,X,i(Xq)	09
46,X,i(Xp)	02
46,XY	63
46,X,del(Xq)	12
46,X,del(Xp)	06
Mos 46,XX/45,X	41
Mos 46,XX/46,X,i(Xq)	37
Mos 45,XX/46,X,(Xq)	05
Mos 45,X/45,idc(Xq)	03
Mos 46,XX/46,XY	13
Mos 45,X/46,XY	09
Mos 45,X/46,XX/46,i(Xq)	06
Mos 45,X/46,XX/46,XY	02
XXX	03
XXY	02
t(X;Y)	02
t(X;11)	01
t(X;7)	01
44,X,der(14;21)t(14;21)	02
46,XX,t(2;12)	01
46,XX,inv(3)	01
<b>Polymorphic variations but Karyotype normal</b>	
(1qh+,16qh+,9qh+,inv(9),inv(9)X2,,13ps+,14ps+, 15ps+,21ps+,22ps+	58
<b>Total</b>	<b>348</b>

Early mortality due to congenital heart disease is unknown but increase in the risk of dissection of the aorta is reported in some studies. Patient with sex chromosome-autosome translocation may have mental

deficiencies and mental retardation is frequently associated small ring X.<sup>10</sup>

Depending upon the cytogenetic findings the consequences may vary. As compared to autosomal

abnormalities the effect of sex chromosomal abnormalities may not be that severe but stature and pubertal development is usually affected as majority of genes responsible for this are present on X chromosomes. The cytogenetic abnormalities usually seen in Turner Syndrome are 45, X or deletion of Xp/Xq or mosaicism for sex chromosomes either with 45, X or 46, XX or 46, XY.<sup>11</sup> Abnormalities of distal short arm of chromosomes are usually associated with somatic development. The most common mosaic pattern seen is 45, X/46,XX and somatic abnormalities are comparatively less as compared to 45,X. Females with 45,X/46,XY or 46, XY is approximately 6% and prophylactic gonadectomy may be life-saving because of possibility of development of gonadoblastoma. Various variant forms are seen in Turner Syndrome mainly 46,X,i(Xq),46,X,del(Xq), 46,X,del(Xp) or 46,X,der(X). In some cases, along with the sex chromosomal abnormalities, some polymorphic variations like pericentric inversion of chromosome 9 inv (9), increase in length of satellite on acrocentric chromosome and increase in the length of heterochromatic region have also been reported.<sup>12-14</sup>

## CONCLUSION

Clinical diagnosis of Turner syndrome is comparatively easy but the cytogenetic confirmation and pattern of chromosomal aberration is very important as early detection may help to improve the quality of life with hormonal therapy and plastic surgery and at times in small group can save the life in patients especially with patients with cytogenetically Turner variant pattern with presence of Y chromosome.

## ACKNOWLEDGEMENTS

The authors would like to express sincere gratitude towards Metropolis Healthcare Ltd, Mumbai for providing the essential facilities to carry out this research.

*Funding: No funding sources*

*Conflict of interest: None declared*

*Ethical approval: The study was approved by the Institutional Ethics Committee*

## REFERENCES

1. Venkateshwari A, Srimanjari K, Srilekha A, Begum A, Sujatha M, Sunitha T, et al. Mosaic triple X syndrome in a female with primary amenorrhea. *Indian J Hum Genet*. 2012;18:246–9.
2. Renna MD, Pisani P, Conversano F, Perrone E, Casciaro E, Renzo GC, et al. Sonographic markers for early diagnosis of fetal malformations. *World J Radiol*. 2013;28:356–71.
3. Peccoz P, Persani L. Premature ovarian failure. *Orphanet J Rare Dis*. 2006;1: 9.
4. Turner CL. Adaptations for viviparity in embryos and ovary of *Anableps Anableps*. *Journal of Morphology*. 1938;62:323-49.
5. Elsheikh M, Dunger DB, Conway GS, Wass JAH. Turner's Syndrome in Adulthood. *Endocrine Reviews*. 2002;23:120–40.
6. Yorifuji T, Muroi J, Mamada M. Analysis of the SRY gene in Turner syndrome patients with Y chromosomal material. *Journal of Medical Genetics*. 2001;38:41.
7. Oliveira RM, Verreschi IT, Lipay MV, Eça LP, Guedes AD, Bianco B. Y chromosome in Turner syndrome: review of the literature. *Sao Paulo Medical Journal*. 2009;127:373-8.
8. Sybert VP, McCauley E. Turner's Syndrome. *N Engl J Med*. 2004;351:1227-38.
9. Chen PC, Chien SC. Prenatal Sonographic Features of Turner Syndrome. *Journal of Medical Ultrasound*. 2007;15:251-7.
10. Fonkalsrud EW, Coulson WF. Management of congenital lymphedema in infants and children. *Ann Surg*. 1973;177:280–5.
11. Zhong Q, Layman LC. Genetic Considerations in the Patient with Turner Syndrome—45,X with or without Mosaicism. *Fertil Steril*. 2012;98:775–9.
12. Mozdarani H, Meybodi AM, Karimi H. Impact of pericentric inversion of Chromosome 9 [inv (9) (p11q12)] on infertility. *Indian J Hum Genet*. 2007;13:26–9.
13. Hong Y, Zhou YW, Tao J, Wang SX, Zhao XM. Do polymorphic variants of chromosomes affect the outcome of in vitro fertilization and embryo transfer treatment? *Hum Reprod*. 2011;26:933–40.
14. Dong Y, Jiang YT, Du RC, Zhang HG, Li LL, Liu RZ. Impact of chromosomal heteromorphisms on reproductive failure and analysis of 38 heteromorphic pedigrees in Northeast China. *J Assist Reprod Genet*. 2013;30:275–81.

**Cite this article as:** Pande S, Salaskar V, Pais A, Pradhan G, Patil S, Parab C, et al. Frequency of turner syndrome: findings from a tertiary healthcare diagnostic laboratory of India. *Int J Community Med Public Health* 2017;4:4333-6.